











CRITICAL REVIEW**Management of ring chromosome 20 syndrome: Narrative review and consensus recommendations**

Asma Khamis¹  | **Emilia Ricci**^{2,3,4}  | **Maria Paola Canevini**^{2,3,4}  |
Lieven Lagae^{5,6}  | **Kentaro Tokumoto**⁷  | **Yushi Inoue**⁷  | **Tim Buckinx**⁸  |
Allison Watson⁸   | **Kenneth A. Myers**^{9,10,11} 

¹Faculty of Medicine and Health Sciences, McGill University, Montreal, Quebec, Canada

²Epilepsy Center, Child Neurology Unit, AAST Santi Paolo Carlo, Milan, Italy

³Member of European Reference Center Epicare

⁴Department of Health Sciences, Università degli Studi, Milan, Italy

⁵Department Paediatric Neurology, University Hospitals KuLeuven, Childhood Epilepsy Center, Leuven, Belgium

⁶Full Member of European Reference Center Epicare

⁷National Epilepsy Center, National Hospital Organization Shizuoka Institute of Epilepsy and Neurological Disorders, Shizuoka, Japan

⁸Ring 20 Research & Support UK CIO, Poole, Dorset, UK

⁹Child Health & Human Development Program, Research Institute of the McGill University Health Centre, Montreal, Quebec, Canada

¹⁰Division of Neurology, Department of Pediatrics, Montreal Children's Hospital, McGill University Health Centre, Montreal, Quebec, Canada

¹¹Department of Neurology and Neurosurgery, Montreal Children's Hospital, McGill University Health Centre, Montreal, Quebec, Canada

Correspondence

Kenneth A. Myers, Montreal Children's Hospital, McGill University Health Centre Glen Site, 1001 Boulevard Décarie, Montreal, QC H4A 3J1, Canada.
 Email: kenneth.myers@mcgill.ca

Abstract

Ring chromosome 20 (ring 20) is a rare genetic condition usually presenting as developmental and epileptic encephalopathy. The disease is caused by fusion of the long and short arms of chromosome 20. Patients are symptomatic even if there is no loss of genetic material. Epilepsy in ring 20 is usually drug-resistant, with seizures often significantly debilitating and severely impacting quality of life. We assembled a taskforce of clinician–scientists with expertise in ring 20, as well as caregivers of individuals with ring 20. We then reviewed published literature on ring 20 with a focus on management with the aim of developing recommendations for the treatment of this disorder. Our review found that there are very few high-quality data available to guide treatment in ring 20. The majority of publications are individual case reports or small case series. Based on these limited data, as well as personal experience, we recommend the following. (1) The care team should be multidisciplinary and include at least an epileptologist and allied health specialists (e.g., speech therapist, occupational therapist, physiotherapist, psychologist); (2) patients and families should be referred for genetic counseling; (3) if patients are diagnosed with epilepsy, they and their families should be counseled that seizures are likely to be drug-resistant and life-long; (4) as there is a

This is an open access article under the terms of the [Creative Commons Attribution-NonCommercial-NoDerivs](https://creativecommons.org/licenses/by-nc-nd/4.0/) License, which permits use and distribution in any medium, provided the original work is properly cited, the use is non-commercial and no modifications or adaptations are made.

© 2026 The Author(s). *Epilepsia* published by Wiley Periodicals LLC on behalf of International League Against Epilepsy.

high incidence of non-convulsive status epilepticus (NCSE), there should be a low threshold for video-EEG monitoring if patients have a change in behavior or level of consciousness; (5) initial epilepsy treatment should be with an oral anti-seizure medication; (6) home rescue medication should be considered given the risk for prolonged seizures and NCSE; (7) for patients with drug-resistant epilepsy, ketogenic diet, vagus nerve stimulation, or deep brain stimulation could all be considered; and (8) caregiver burnout and stress should be screened for and supports provided.

KEYWORDS

developmental and epileptic encephalopathy, epilepsy, non-convulsive status epilepticus, ring chromosome, ring chromosome 20

1 | INTRODUCTION

Ring chromosome 20 (ring 20) syndrome is a rare condition characterized by epilepsy, with the majority also having intellectual disability (ID).¹ The syndrome arises from a rare genetic event whereby intra-chromosomal breakage and fusion occur between the short and long arms of chromosome 20, forming a ring shape with or without loss of genetic material.¹ Ring chromosomes usually arise de novo during embryonic development, although parental transmission has been reported.^{1,2} Individuals with ring 20 also display varying cellular mosaicism, with the degree of mosaicism correlating significantly with the age at seizure onset and severity of cognitive impairment.³ The mechanisms by which these changes result in seizure development and other phenotypic abnormalities are not yet well-understood, especially because ring 20 signs and symptoms can arise without deletion of coding genetic material.² The first patients with ring 20 were described in 1972, and fewer than 200 individuals have since been reported in the literature; incidence and prevalence are unknown, but unsuccessful attempts at estimation indicate that it is an ultra-rare condition.^{1,4,5}

Although the majority of people with ring 20 have at least some degree of ID, initial developmental milestones are usually normal.^{1,6,7} Prior to epilepsy onset, abnormal development is reported in only ~15%^{6,7}; however, development regression or plateau may occur in concert with the appearance of seizures, consistent with a developmental and epileptic encephalopathy (DEE).⁸ The epilepsy phenotype can be variable, but most commonly involves focal seizures, usually drug-resistant, and non-convulsive status epilepticus (NCSE) has frequently been reported.^{1,6} Some individuals may exhibit attention deficit, impulsivity, behavioral dysfunction, impaired speech and executive abilities, and loss of social skills.¹ Dysmorphic features have been reported in a minority of people with ring 20;

when present, these are usually subtle, with described features including microcephaly, dental malocclusions, and cauliflower-shaped ears.^{1,9,10}

Ring 20 is likely underdiagnosed, as identification of ring chromosomes often requires a conventional karyotype, a test that is less commonly performed since the advent of readily available next-generation DNA sequencing. In patients with complete ring chromosomes (i.e., no deleted genetic material), chromosomal microarray, gene panels, and whole exome/genome sequencing may all be normal.

Because of the rarity of ring 20, determining optimal clinical management is challenging. There are no well-conducted clinical trials for this disorder, and the literature is composed primarily of case reports and case series. Given the potentially serious and complex presentations of people with ring 20, management must take into account all aspects of the disorder, optimize multidisciplinary care, and consider the impact on families and caregivers. Therefore, this narrative review has been prepared with the aim of consolidating current research on existing treatment modalities and providing guidance regarding clinical management of patients with ring 20.

2 | MATERIALS AND METHODS

A “Ring Chromosome 20 Research and Support – Treatment Task Force” was formed, composed of an international group of clinician-scientists with expertise in ring 20 (K.A.M., L.L., Y.I., K.T., M.P.C., and E.R.) and the CEO and Trustee from Ring20 Research and Support representing input from the global ring 20 community (A.W. and T.B.). For clinician–scientists, “expertise” was defined as having published at least one peer-reviewed research article on the topic of ring 20. The task force developed a plan for this project, involving a narrative literature

review followed by consensus recommendations. The latter would be based on the results of the literature review but also informed by the task force members' own experiences.

2.1 | Narrative review

A literature search was conducted, aimed at identifying articles related to the treatment and management of people with ring 20.

2.1.1 | Database searched

PubMed.

2.1.2 | Date of last search

March 26, 2025.

2.1.3 | Core search terms

The following keyword combinations were used: (“ring chromosome 20 syndrome” or “ring 20 syndrome” or “r20 syndrome” or “ring chromosome 20”) and ((“therapy” or “treatment” or “management”) or (“vagus nerve stimulation” or “VNS” or “stimulation”)); “epilepsy” and “deep brain stimulation” and (“refractory” or “drug-resistant” or “drug-resistance” or “resistance”); (“ring chromosome 20 syndrome” or “ring 20 syndrome” or “r20 syndrome” or “ring chromosome 20”) and “drug-resistant epilepsy.”

2.1.4 | Inclusion period

From 1970 to the date of the search.

2.1.5 | Language restrictions

Only English-language articles were included.

2.1.6 | Inclusion criteria

Publications were included if they had elements related to any aspect of clinical management of ring 20, including pharmacological and non-pharmacological treatment modalities, multidisciplinary contributions, and caregiver

Key points

- Patients with ring chromosome 20 (ring 20) should have a multidisciplinary care team, including at least an epileptologist and allied health care specialists.
- Initial epilepsy treatment in ring 20 should be with an oral anti-seizure medication, although no one agent is clearly superior.
- For patients with drug-resistant epilepsy, the ketogenic diet, vagus nerve stimulation, and deep brain stimulation could all be considered.
- Ring 20 can have a significant impact on caregivers, so proper counseling and support of families is essential.
- There are very limited data in the literature regarding optimal treatment of ring 20; more research is crucial to address this knowledge gap.

support. We included all peer-reviewed manuscript types, including but not limited to: case reports, case series, review papers, and original research articles. Non-peer-reviewed materials (e.g., abstracts) were not included. Both qualitative and quantitative data were included. Studies including mixed populations were considered eligible for inclusion, as long as data specific to ring 20 patients could be extracted.

2.1.7 | Handling of duplicates

Duplicate publications were removed. If the same patient was mentioned in multiple publications, all data were extracted; however, the patient was counted only once when presenting statistics.

Reference lists of the identified papers were reviewed in an effort to identify additional relevant publications. A medical student (A.K.) screened the titles and abstracts of all identified citations to review them for inclusion in the final analysis. The data were extracted and synthesized by A.K.

2.2 | Consensus recommendations

2.2.1 | Consensus panel

The consensus panel included seven individuals: four pediatric epileptologists (L.L., K.A.M., M.P.C., and E.R.), two adult epileptologists (K.T. and I.N.), and two parents of individuals with ring 20 (T.B. and A.W.). Five were

Study type	Number of studies included in data analysis	Total number of ring 20 patient descriptions with available data
Case report	19	19
Case series	11	72
Cohort study	2	48
Cross-sectional survey	1	42
Meta-analysis	1	3 (all already included from case reports)
Molecular studies with clinical data reported	1	7
Open-label prospective clinical trials	0	0
Randomized clinical trials	0	0

TABLE 1 Study types included in data analysis.

based in Europe, two in Asia, and one in North America. All the epileptologists were based in tertiary epilepsy centers.

2.2.2 | Statement drafting

An initial draft of recommendations was prepared by A.K. and K.A.M. based on the results of the literature review and the clinical experience of K.A.M. This draft was circulated to the full task force for review prior to meetings to discuss revisions.

2.2.3 | Consensus process

Consensus on recommendations was reached through two virtual meetings and additional e-mail communications. At each stage, task force members provided comments to A.K. and K.A.M., who incorporated the feedback and recirculated an updated version. As the task force was small, 100% consensus was necessary for a statement to be included.

Results of the literature search were reviewed and recommendations discussed over a series of online task force meetings, as well as via email correspondence. The recommendations were repeatedly revised until all task force members were in agreement. Recommendations were based primarily on available published data, but personal experience of task force members (including patient experts) was also considered. A level of evidence was assigned to each recommendation based on the Grading of Recommendations, Assessment, Development, and Evaluation (GRADE) approach, as has been suggested by the International League Against Epilepsy (ILAE).¹¹

3 | RESULTS

3.1 | Narrative synthesis

Data were extracted from 35 publications (summarized in [Table 1](#), details in [supplementary material](#)). These publications consist of 19 case reports comprising 19 patients, 11 case series comprising 72 patients, 2 cohort studies comprising 48 patients, 1 cross-sectional survey comprising 42 patients, 1 meta-analysis comprising 3 patients, and 1 molecular study with clinical data reported, comprising 7 patients. No randomized trials were identified. In total, 188 unique patients with ring 20 were identified. A variety of pharmacological and non-pharmacological interventions were identified and are discussed by category. The number of publications that included data for each specific category is summarized in [Table 2](#).

3.1.1 | Pharmacologic agents

From the literature, lamotrigine and valproic acid appear to most consistently show positive results in the treatment of epilepsy. A cohort study of 47 ring 20 patients showed that of the 30% who were drug-responsive, lamotrigine was effective in 69% and valproic acid was effective in 43%.⁶ Here, treatment improved seizures to a degree minimally disruptive to daily life.⁶ In another ring 20 cohort study including 24 people with ring 20 and epilepsy, the combination of lamotrigine and valproic acid improved seizure control in eight patients.⁷ This treatment combination was also reported to improve seizure control in five other ring 20 patients across several other case reports.^{8,12,13}

In addition, there are data, mostly from case reports, suggesting that certain anti-seizure medications (ASMs)

TABLE 2 Number of studies with data relevant to specific therapeutic categories.

Intervention	Number of studies with relevant data	Total number of ring 20 patient descriptions with relevant data ^a	Direction of effect
ASM	31	125	Mixed responses depending on specific medication. LTG and VPA had the most consistently positive reports of therapeutic benefit
Ketogenic diet	8	52	Mixed responses. In one cohort of 20 patients assessed by questionnaire, improvement in seizures in 30% and cognition and alertness in 30%
Corticosteroids	7	8	Only 1 of 8 (12.5%) reported significant benefit (20–40 seizures per day pre-treatment, which reduced to 2–3 seizures per week, with concurrent cognitive and functional improvement)
VNS	11	25	Mixed results, although some reports of dramatic improvement in individual patients. The largest case series reported some improvement in 11 of 14 (79%)
DBS	2	3	Of 3 reported patients, 1 had improvement, 1 no change, and 1 worsening in seizures
RNS	1	1	The 1 reported patient had been recently implanted; clinical response was not yet clear
Corpus callosotomy	4	4	Of 4 patients, 2 (50%) had no benefit, 1 (25%) had significant seizure improvement, and 1 (25%) had less severe seizures, but no change in frequency
Surgical resection	3	4	Overall ineffective. No patients had sustained clinical benefit
IVIg	1	1	No benefit
Lithium	1	1	In 1 patient, marked improvement in behavior and psychiatric symptoms, as well as >95% reduction in seizure frequency

Abbreviations: ASM, antiseizure medication; DBS, deep brain stimulation; IVIg, intravenous immunoglobulin; RNS, responsive neurostimulation; VNS, vagus nerve stimulation.

^aIn calculating the number of ring 20 patients with available data, we attempted to only count once the patients who were reported in multiple publications; however, it is possible that not all duplicate reports were accounted for.

may elicit significant positive results in individual patients; these include lacosamide,^{14–16} zonisamide,¹⁷ ezogabine,¹⁸ felbamate,¹⁹ perampanel,^{20,21} and gabapentin.¹⁶ Based on the limited available literature, certain ASMs appear less likely to improve seizure control in ring 20; these include primidone, ethosuximide, and clobazam.^{17,22,23} However, data for or against use of specific agents based solely on individual case reports is of very limited clinical utility.

Several pharmacologic agents that are not commonly prescribed to people with epilepsy have been reported in isolated case reports to improve seizure control in ring

20. An 11-year-old with ring 20 received intravenous methylprednisolone for five consecutive days per month for 9 months, and then tapered.²⁴ Pre-treatment, he had 20–40 seizures per day, which reduced to 2–3 times per week after the first five doses, and he also became more alert and active, and he was able to resume schooling. However, other patients have been reported with little to no positive response to corticosteroids,^{6,8,21,25–28} so the benefits are certainly not universal.

Lithium is another alternative therapeutic option for people with ring 20 who also present with psychiatric

manifestations. Inal et al. described a 12-year-old with ring 20 and drug-resistant epilepsy (DRE), who was prescribed lithium for bipolar disorder, characterized by fluctuations between depressive-like and manic-like psychiatric symptoms so severe that they necessitated psychiatric hospitalization.²⁹ In addition to marked improvement in behavior and psychiatric symptoms, the patient's seizure frequency decreased from two to three per day to less than one per week.

Cannabidiol has received much attention as a therapeutic option for patients with epilepsy; however, there are few data available for people with ring 20. A "real world" study examining the effect of cannabidiol as add-on therapy in DRE included one patient with ring 20; however, no individual data on clinical response were available, other than a note that the patient had developed elevated serum aminotransferases.³⁰

3.1.2 | Ketogenic diet

The ketogenic diet (KD) is a high-fat, carbohydrate-restricted diet often considered in patients with DRE.^{31,32} In a survey of caregivers of people with ring 20 who had trialed the KD, nearly half reported benefit—6 of 20 reported significant improvement in seizures and 3 reported mild improvement.³¹ Tokumoto et al. reported three ring 20 patients treated with the KD, and one who tried the modified Atkins diet; however, none reported positive effects.⁶ Some caregivers of people with ring 20 noted that there can be challenges to implementing the diet including restricted meal options, maintaining the diet while socializing or dining out, planning ahead, and maintaining the diet in patients with comorbidities such as attention-deficit/hyperactivity disorder (ADHD), autism, and severe cognitive impairment.³¹

3.1.3 | Vagus nerve stimulation

Vagus nerve stimulation (VNS) is an established treatment for people with DRE who are not candidates for surgical resection.³³ In a recently published case series of 14 patients with ring 20 who underwent VNS implantation, 11 (79%) reported some improvement.³⁴ This included five with reported seizure frequency reduction, three reporting reduced seizure duration, three reporting decreased frequency of NCSE or specific seizure types, two with reduced need for rescue medication, and two with shorter post-ictal signs/symptoms.

The remainder of the VNS data for ring 20 come primarily from individual case reports or small case series in which the results are mixed, overall.^{6,7,12,25–27,33,35–40}

There are some dramatic positive reports, such as a 6-year-old girl with ring 20 who experienced seizures from birth that were resistant to treatment with 10 ASMs, intravenous methylprednisolone, and the KD. Following VNS implantation and titration, she became seizure-free and was reported to have greater alertness, less lethargy, and began to speak, having been previously nonverbal.²⁶ However, there are also many reports of patients who experienced no benefit or had only a marginal positive response.

3.1.4 | Deep brain stimulation

Although deep brain stimulation (DBS) is already a therapeutic mainstay of Parkinson's disease and other movement disorders, there are also data indicating effectiveness in certain forms of epilepsy.⁴¹ The two most promising anatomic targets are the thalamic anterior nucleus for focal and secondarily generalized forms of epilepsy, and the thalamic centromedian nucleus for Lennox–Gastaut syndrome.⁴¹ Although more data are available for adults with epilepsy, a systematic review identified data from 72 children with DBS; >50% seizure reduction was reported in 75%, and the intervention was otherwise generally well-tolerated.⁴²

With respect to ring 20 specifically, we were only able to identify three reports of patients having DBS. Arévalo-Sáenz et al. reported a 43-year-old woman with ring 20 and epilepsy from age 6 years that was drug resistant.⁴³ She had DBS implantation of the centromedian nucleus; however, no significant clinical improvement was observed. The cohort described by Lajoie et al. included two patients with DBS; one had improvement in seizure control; however, the other had worsening of seizure control so the DBS was deactivated.³⁴

3.1.5 | Responsive neurostimulation

Responsive neurostimulation (RNS) is unique from VNS and DBS because it is a closed-loop paradigm, meaning that it adapts its therapeutic output in real time based on physiological feedback.⁴¹ Thus, RNS administration is particularly well suited to seizures arising from the eloquent cortex, which are regions crucial for essential functions like language, motor control, and sensory processing.⁴¹ We identified one case series that included a patient with ring 20 who had RNS implantation; however, the authors reported that the implantation was very recent and there were insufficient data to conclude whether or not it was effective.³⁴ Although this intervention could be potentially beneficial, it is not yet

clear how it would be best implemented in this patient population.

3.1.6 | Other surgical interventions

Tokumoto et al. reported three ring 20 patients who underwent focal resection, none of whom had any significant benefit⁶; one of the three patients was separately reported to have seizures “reduced considerably” initially,⁴⁴ but this was not sustained. Myers et al. also reported a ring 20 patient who had two right parietal resections prior to receiving the genetic diagnosis; neither procedure elicited any significant clinical improvement.⁴⁵

We identified four ring 20 patients who underwent corpus callosotomy. The patient reported by Alpman et al. with ring 20 and Lennox–Gastaut phenotype (previously mentioned in VNS section) who had tonic seizures refractory to both pharmacologic treatment and VNS, had a corpus callosotomy at age 13 years.³⁵ The authors reported that there was no improvement in seizure frequency or behavior, but that seizures became less intense. Tokumoto et al. reported an additional patient with corpus callosotomy, who did not experience significant clinical improvement.⁶ García-Cruz et al. reported that corpus callosotomy significantly improved seizure frequency in a male patient with ring 20 and DRE.¹⁹ Finally, Zou et al. reported an adult female with ring 20 and DRE who had a corpus callosotomy, but they did not note any significant benefit.³⁷

3.1.7 | Management of comorbidities

In addition to epilepsy and ID, people with ring 20 have been reported to have a range of cognitive deficits, psychiatric disorders, and behavioral dysfunction, which may or may not be related to cerebral epileptic activity.⁸ These include language deficits, disorientation, apathy, agitation, hyperphagia, pica, loss of emotional facial expression, cognitive slowing, aggression, reckless behavior, impairment in adaptive behavior and social skills, motor skills deficits, executive dysfunction, obsessive-compulsive traits, and autism.^{8,46} Although ASMs may improve these signs and symptoms in the context of a DEE,⁸ there are often persistent issues so patients may require involvement of specialists to aid in management. These could include speech-language pathologists, occupational therapists, physiotherapists, psychologists, and psychiatrists. It is also important to consider that the effects of ASMs and other drugs might exacerbate certain co-morbidities (e.g., levetiracetam can exacerbate behavioral issues).

3.1.8 | Family stress and burden

Caregivers of people with ring 20 have expressed a need for support, and have noted that their neurology teams (particularly in adult care) are often unfamiliar with the disorder.²⁷ In general, caregiver stress and burden are markedly increased for people with epilepsy, and having DRE has been identified as independently increasing stress and burden in this population.⁴⁷

3.2 | Consensus recommendations

3.2.1 | Care team

All people with ring 20 should be followed by a neurologist, preferably an epileptologist (Figure 1) (quality of evidence “moderate”). Given the high incidence of DRE, early referral to a tertiary/quaternary epilepsy center should be made, if possible (quality of evidence “moderate”). As patients can have a range of developmental profiles, affected children should have evaluations by speech therapy, physiotherapy, and occupational therapy, and ongoing therapy should be organized in order to optimize the individual's long-term developmental trajectory (quality of evidence “low” due to lack of ring 20–specific data). For school-age children, a neuropsychological evaluation should be conducted, with the results used to find the most appropriate educational environment and optimize the learning plan (quality of evidence “low” due to lack of ring 20–specific data). If there are significant behavioral issues, consultation with a psychologist and/or psychiatrist should be considered, ideally specialists with experience treating children and/or adults with neurodevelopmental disorders (quality of evidence “low” due to lack of ring 20–specific data).

As well, the stress and burden on caregivers of people with ring 20 should be monitored and addressed accordingly. If there are symptoms of burn-out, mood disorder, or other mental health issue, caregivers should be referred to psychology and/or psychiatry. Caregivers should also be offered respite care and other supports, if available (quality of evidence “low” due to lack of ring 20–specific data).

Furthermore, as many ring 20 patients are diagnosed in childhood and are thus initially followed by a pediatric care team, attention must be given to ensuring smooth transition to adult care (quality of evidence “low” due to lack of ring 20–specific data). Beginning in early adolescence, the patient and their family should be prepared for the eventual transition and the relevant issues surrounding it. This may include some or all of the following: receiving care at a new geographic location, less access to certain services (e.g., psychologists, dietitians,

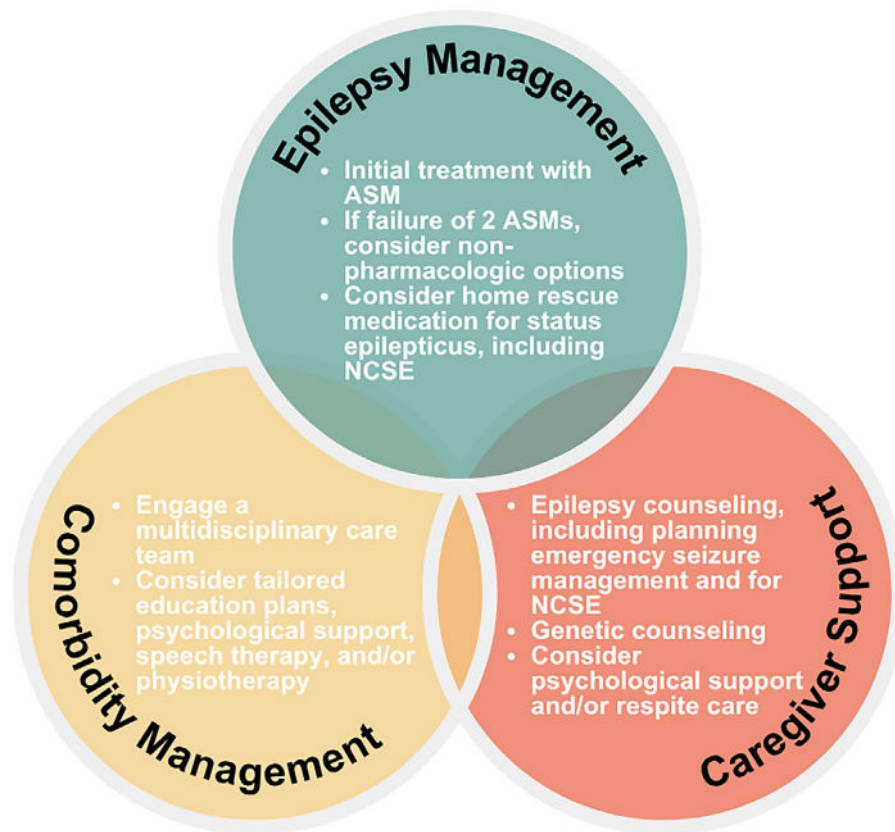


FIGURE 1 Summary of recommendations.

occupational therapists, speech-language therapists) or treatments, and increased autonomy.⁴⁸

3.2.2 | Genetic counseling

Given the complex molecular pathophysiology of ring 20, referral to genetic counseling should be offered (quality of evidence “low” due to lack of ring 20–specific data). Discussions could include explanation of mosaicism, the prognosis of the disorder, and inheritance risk for other family members.

3.2.3 | Epilepsy counseling

If seizures are diagnosed, the patient’s family should be counseled that there is a significant possibility that seizures will be life-long and drug resistant (quality of evidence “high”). Patients may have developmental plateau or regression at the time of seizure onset, in keeping with a DEE. NCSE should be discussed, and caregivers should be instructed on warning signs for this entity (quality of evidence “high”). Counseling should also include discussion of emergency seizure management, seizure safety precautions, and sudden unexpected death

in epilepsy (quality of evidence “low” due to lack of ring 20–specific data).

3.2.4 | Use of video-EEG monitoring

The signs and symptoms of NCSE include drowsiness, moodiness, or feeling unwell. This may not be recognized as a seizure or may be mistaken for a side effect of medication. For any unusual events, video-EEG monitoring should be considered to evaluate if the clinical change can be attributed to seizures (quality of evidence “low”). The EEG findings of NCSE in patients with ring 20 may still be prominent, even after clinical symptoms have lessened.

3.2.5 | Epilepsy treatment

For patients with epilepsy, initial therapy should be with an oral ASM (quality of evidence “low” due to lack of ring 20–specific data). The current evidence is insufficient to strongly recommend any particular medications, so the specific ASM can be chosen based on the patient’s specific seizure type(s) and overall medical and psychological profile. Based on the limited available literature, reasonable

first-line medications for most patients include valproic acid, lamotrigine, and other sodium channel antagonists (quality of evidence “low”). If seizures are not controlled by the initial ASM, a second ASM should be tried; combination therapy with lamotrigine and valproic acid has worked well in some patients (quality of evidence “low”). For newer agents (e.g., cenobamate, cannabidiol), there are very limited data, and efficacy is not yet clear in ring 20.

Given the risk of status epilepticus, including NCSE, a home rescue medication, such as rectal diazepam, intranasal/buccal midazolam, or sublingual lorazepam, should be considered (quality of evidence “low”). Patients with a history of status epilepticus should ideally have a written protocol (individual care plan) for management of status epilepticus including NCSE (quality of evidence “low”). This protocol could include both home rescue medications and a plan for more aggressive intervention in the emergency room or intensive care unit, if necessary. Some clinicians may recommend use of home medication earlier for convulsive seizures (e.g., 5 min) than NCSE (e.g., 30 min), particularly if patients tend to require long recovery times from the rescue medication (quality of evidence “very low”). Status epilepticus protocols should be written clearly and concisely, with the aim of facilitating timely care if patients need to go to hospital. Protocols should be individualized to the patient's goals of care and specific medical profile.

If patients have ongoing seizures despite trials of two ASMs, a discussion of non-pharmacologic interventions should be undertaken (quality of evidence “low” due to lack of ring 20-specific data). This can include some or all of the following, depending on the resources available: KD, VNS, DBS.

Corpus callosotomy could be considered as a palliative procedure in patients with frequent, highly problematic, tonic or atonic seizures (quality of evidence “low” due to lack of ring 20-specific data). RNS is a potentially good candidate intervention (quality of evidence “very low” due to lack of ring 20-specific data); however, there are currently essentially no data regarding effectiveness in ring 20, and the optimal method for implementation is not clear. Surgical resection is not recommended, as such interventions are very unlikely to be effective and could have significant complications (quality of evidence “low”). Concurrent to discussion and implementation of non-pharmacologic interventions, there should be ongoing efforts to optimize medical therapy, and trials of corticosteroids or other agents could be considered (quality of evidence “low”).

Considering that a large proportion of people with ring 20 will have drug-resistant epilepsy, management should always be aimed at optimizing quality of life, rather than controlling seizures at all costs. In particular, efforts should be made to minimize polypharmacy and avoid exposing patients to medication side effects unnecessarily.

4 | DISCUSSION

Ring 20 is a rare condition that usually presents as a DEE and is likely still underdiagnosed, which means that treatment evidence specific to this syndrome is still sparse. Even for published case reports, lack of follow-up on the long-term effects of certain therapies presents a limitation when making recommendations. Furthermore, seizures in ring 20 are frequently drug resistant, necessitating continued innovation in existing standards of care for diseases with epileptic phenotypes. Although standard ASMs should continue to be used as first-line treatment, non-pharmacologic approaches should be considered early in drug-resistant patients. Feasibility, availability, and other patient-specific factors should guide the discussion and be integral to the shared decision-making process between health care providers, patients, and their families and caregivers.

The recommendations made herein are based on very limited evidence, which highlights the need for more research into ring 20. A limitation of the study is that only one individual reviewed references identified in the literature search, which could be a source of bias. Prospective studies with close, regular follow-up are needed to determine how best to utilize existing therapies, both medical and surgical. Much of the published data predate newer ASMs for which efficacy in ring 20 should be investigated. We also noted a distinct paucity of data regarding emergency medications for status epilepticus, including NCSE; this is a particular area in which more robust clinical data are needed. In addition to such clinical studies, a better understanding of the underlying pathophysiology of ring 20 is necessary to facilitate the development of precision therapies, as well as for planning how such treatments should be modified as the condition progresses over the life course. The development of in vivo and in vitro models, as well as disease biomarkers, is essential for the discovery and evaluation of novel, targeted therapies. Such advancements could eventually improve clinical management of patients with ring 20, ultimately contributing to favorable health outcomes and optimizing quality of life.

AUTHOR CONTRIBUTIONS

Asma Khamis: data collection, writing – original draft preparation, figure preparation. Emilia Ricci: writing – review and editing, figure preparation. Maria Paola Canevini: conceptualization, writing – review and editing. Lieven Lagae – conceptualization, writing – review and editing. Kentaro Tokumoto: writing – review and editing. Yushi Inoue – writing – review and editing. Tim Buckinx: conceptualization, writing – review and editing. Allison Watson: conceptualization, writing – review and editing. Kenneth A. Myers: conceptualization, writing – review and editing, supervision.

ACKNOWLEDGEMENTS

None.

FUNDING INFORMATION

This project was not supported by specific funding.

CONFLICT OF INTEREST STATEMENT

Dr. Myers has served as a paid consultant for Jazz Pharmaceuticals, UCB, and Pendopharm. Tim Buckinx is the founder/CEO of Epihunter. The remaining authors have nothing to disclose. We confirm that we have read the Journal's position on issues involved in ethical publication and affirm that this report is consistent with those guidelines.

DATA AVAILABILITY STATEMENT

No data were generated in this work.

ETHICS STATEMENT

Research ethics board approval was not required for this project.

PATIENT CONSENT STATEMENT

Human patients were not involved in this project.


PERMISSION TO REPRODUCE MATERIAL FROM OTHER SOURCES

Not applicable.

ORCID

Asma Khamis  <https://orcid.org/0009-0001-8186-0525>

Emilia Ricci  <https://orcid.org/0000-0002-3405-6454>

Maria Paola Canevini  <https://orcid.org/0000-0002-2292-4015>

Lieven Lagae  <https://orcid.org/0000-0002-7118-0139>

Kentaro Tokumoto  <https://orcid.org/0000-0002-2502-5496>

Yushi Inoue  <https://orcid.org/0000-0001-7654-036X>

Tim Buckinx  <https://orcid.org/0009-0003-7685-1768>

Allison Watson  <https://orcid.org/0000-0001-7201-9710>

Kenneth A. Myers  <https://orcid.org/0000-0001-7831-4593>

TWITTER

Allison Watson  Ring20uk

REFERENCES

- Peron A, Catusi I, Recalcati MP, Calzari L, Larizza L, Vignoli A, et al. Ring chromosome 20 syndrome: genetics, clinical characteristics, and overlapping phenotypes. *Front Neurol*. 2020;11:613035.
- Myers KA. Ring chromosome 20. In: Li PLT, editor. *Human ring chromosomes - a practical guide for clinicians and families*. Switzerland: Springer; 2024.
- Conlin LK, Kramer W, Hutchinson AL, Li X, Riethman H, Hakonarson H, et al. Molecular analysis of ring chromosome 20 syndrome reveals two distinct groups of patients. *J Med Genet*. 2011;48(1):1-9.
- Atkins L, Miller W, Salam M. A ring-20 chromosome. *J Med Genet*. 1972;9(3):377-80.
- Barbour K, Tian N, Yozawitz EG, Wolf S, McGoldrick PE, Sands TT, et al. Population-based study of rare epilepsy incidence in a US urban population. *Epilepsia*. 2024;65(8):2341-53.
- Tokumoto K, Nishida T, Ikeda H, Ikeda H, Kawaguchi N, Mizutani S, et al. Long-term seizure and psychosocial outcomes of patients with ring chromosome 20 syndrome: a cohort study of 47 cases. *Epilepsia*. 2025;66:2444-53.
- Vignoli A, Bisulli F, Darra F, Mastrangelo M, Barba C, Giordano L, et al. Epilepsy in ring chromosome 20 syndrome. *Epilepsy Res*. 2016;128:83-93.
- Vignoli A, Canevini MP, Darra F, La Selva L, Fiorini E, Piazzini A, et al. Ring chromosome 20 syndrome: a link between epilepsy onset and neuropsychological impairment in three children. *Epilepsia*. 2009;50(11):2420-7.
- Patil AA, Vinayan K, Roy AG. Epilepsy in ring chromosome 20 syndrome might have variable clinical features. *Ann Indian Acad Neurol*. 2020;23(5):718-22.
- García DM, Ortiz R, Gómez A, Barriuso E. Ring 20 chromosome syndrome with epilepsy and dysmorphic features: a case report. *Epilepsia*. 2001;42(12):1607-10.
- Sauro KM, Wiebe S, Perucca E, French J, Dunkley C, de Marinis A, et al. Developing clinical practice guidelines for epilepsy: a report from the ILAE Epilepsy Guidelines Working Group. *Epilepsia*. 2015;56(12):1859-69.
- Borković M, Čuturilo G, Cerovac N. Ring chromosome 20: a further contribution to the delineation of epileptic phenotype. *Vojnosanit Pregl*. 2022;79(2):196-200.
- Balabhadra A, Parekh M, Patil A, Jayalakshmi S. A case of drug-resistant epilepsy associated with ring chromosome 20. *Ann Indian Acad Neurol*. 2021;24(5):805-7.
- Tayama T, Mori T, Goji A, Toda Y, Kagami S. Improvement of epilepsy with lacosamide in a patient with ring chromosome 20 syndrome. *Brain Dev*. 2020;42(6):473-6.
- Onder H, Tezer FI. Significant improvements of EEG and clinical findings with oral lacosamide in a patient with ring chromosome 20. *Clin EEG Neurosci*. 2016;47(4):330-2.
- Yamagishi H, Goto M, Osaka H, Kuwajima M, Muramatsu K, Yamagata T. Praxis-induced reflex seizures in two Japanese cases with ring chromosome 20 syndrome. *Epileptic Disord*. 2020;2:214-8.
- Parravicini S, Pasca L, Zanaboni MP, Varesio C, Rognone E, Totaro M, et al. Electroclinical improvement in a patient with ring chromosome 20 syndrome treated with Zonisamide: a case report. *J Pediatr Genet*. 2023;12(3):219-23.
- Walleigh DJ, Legido A, Valencia I. Ring chromosome 20: a pediatric potassium channelopathy responsive to treatment with ezogabine. *Pediatr Neurol*. 2013;49(5):368-9.
- García-Cruz D, Vásquez AI, Perez-Rulfo D, Dávalos NO, Penaloza JM, Garcia-Ortiz JE, et al. Ring-20-syndrome and loss of telomeric regions. *Annales de genetique*. 2000;43(3-4):113-16.
- Ling J, Yeung WL, Hon KL, Lo IF, Luk H-M, Fung CW, et al. Successful treatment of drug-resistant seizures secondary to ring 20 mosaicism with perampanel as an add-on antiepileptic drug. *Case Rep Pediatr*. 2022;2022(1):7414628.

21. Shelton A, Tromans SJ, Bhaumik S, Kiani R. Psychosis and epilepsy in ring chromosome 20 syndrome. *Adv Ment Health Intellect Disabil.* 2017;11(1):8–16.
22. Canevini MP, Sgro V, Zuffardi O, Canger R, Carrozzo R, Rossi E, et al. Chromosome 20 ring: a chromosomal disorder associated with a particular electroclinical pattern. *Epilepsia.* 1998;39(9):942–51.
23. Hirano Y, Oguni H, Nagata S. Refractory and severe status epilepticus in a patient with ring chromosome 20 syndrome. *Brain Dev.* 2016;38(8):746–9.
24. Kishore VK, Viswanathan LG, Asranna A, Kenchiah R, Sinha S. Intravenous methylprednisolone is a potential add on therapy for ring chromosome 20 syndrome. *Seizure.* 2022;96:118–20.
25. Parr J, Pang K, Mollett A, Zaiwalla Z, Selway R, McCormick D, et al. Epilepsy responds to vagus nerve stimulation in ring chromosome 20 syndrome. *Dev Med Child Neurol.* 2006;48(1):80.
26. Chawla J, Sucholeiki R, Jones C, Silver K. Intractable epilepsy with ring chromosome 20 syndrome treated with vagal nerve stimulation: case report and review of the literature. *J Child Neurol.* 2002;17(10):778–80.
27. Watson A, Watson D, Taylor C. Life with r (20)—ring chromosome 20 syndrome. *Epilepsia.* 2015;56(3):356–8.
28. Jacobs J, Bernard G, Andermann E, Dubeau F, Andermann F. Refractory and lethal status epilepticus in a patient with ring chromosome 20 syndrome. *Epileptic Disord.* 2008;10(4):254–9.
29. Inal A, Chaumette B, Soleimani M, Guerrot AM, Goldenberg A, Lebas A, et al. Lithium improved behavioral and epileptic symptoms in an adolescent with ring chromosome 20 and bipolar disorder not otherwise specified. *Clin Case Reports.* 2018;6(11):2234–9.
30. Vicino W, Muccioli L, Pondrelli F, Licchetta L, Stipa C, Mostacci B, et al. Real-world experience with cannabidiol as add-on treatment in drug-resistant epilepsy. *Seizure Eur J Epilepsy.* 2023;111:39–41.
31. Gordon D, Watson A, Desurkar A, Cowley L, Hiemstra TF. Assessing the role of ketogenic dietary therapy in ring chromosome 20 syndrome: a patient-led approach. *Epilepsia Open.* 2020;5(2):295–300.
32. Neal EG, Chaffe H, Schwartz RH, Lawson MS, Edwards N, Fitzsimmons G, et al. The ketogenic diet for the treatment of childhood epilepsy: a randomised controlled trial. *Lancet Neurol.* 2008;7(6):500–6.
33. Hajtovic S, LoPresti MA, Zhang L, Katlowitz KA, Kizek DJ, Lam S. The role of vagus nerve stimulation in genetic etiologies of drug-resistant epilepsy: a meta-analysis. *J Neurosurg Pediatr.* 2022;29(6):667–80.
34. Lajoie A, Dufresne D, Hrazdil C, Riou É, Myers KA. Response to vagus nerve stimulation in people with ring chromosome 20. *Seizure Eur J Epilepsy.* 2025;132:13–9.
35. Alpman A, Serdaroglu G, Cogulu O, Tekgul H, Gokben S, Ozkinay F. Ring chromosome 20 syndrome with intractable epilepsy. *Dev Med Child Neurol.* 2005;47(5):343–6.
36. Herrgård E, Mononen T, Mervaala E, Kuusela L, Äikiä M, Stenbäck U, et al. More severe epilepsy and cognitive impairment in the offspring of a mother with mosaicism for the ring 20 chromosome. *Epilepsy Res.* 2007;73(1):122–8.
37. Zou YS, Van Dyke DL, Thorland EC, Chhabra HS, Michels VV, Keefe JG, et al. Mosaic ring 20 with no detectable deletion by FISH analysis: characteristic seizure disorder and literature review. *Am J Med Genet A.* 2006;140(15):1696–706.
38. Macleod S, Mallik A, Tolmie JL, Stephenson JB, O'Regan ME, Zuberi SM. Electro-clinical phenotypes of chromosome disorders associated with epilepsy in the absence of dysmorphism. *Brain Dev.* 2005;27(2):118–24.
39. Alsubhi S, Berrahmoune S, Dudley RW, Dufresne D, Simard Tremblay E, Srouf M, et al. Utility of genetic testing in the pre-surgical evaluation of children with drug-resistant epilepsy. *J Neurol.* 2024;271(5):2503–8.
40. Cappanera S, Passamonti C, Zamponi N. New association between ring chromosome 20 syndrome and hypomelanosis of Ito. *Pediatr Neurol.* 2011;45(5):341–3.
41. Gouveia FV, Warsi NM, Suresh H, Matin R, Ibrahim GM. Neurostimulation treatments for epilepsy: deep brain stimulation, responsive neurostimulation and vagus nerve stimulation. *Neurotherapeutics.* 2024;21(3):e00308.
42. Khan M, Paktiawal J, Piper RJ, Chari A, Tisdall MM. Intracranial neuromodulation with deep brain stimulation and responsive neurostimulation in children with drug-resistant epilepsy: a systematic review. *J Neurosurg Pediatr.* 2021;29(2):208–17.
43. Arevalo-Saenz A, Torres CV, Pastor J, Alonso-Cerezo C, Sola RG. Stimulation of the centromedian nucleus in refractory epilepsy associated to ring chromosome 20. *Rev Neurol.* 2015;60(12):548–52.
44. Inoue Y, Fujiwara T, Matsuda K, Kubota H, Tanaka M, Yagi K, et al. Ring chromosome 20 and nonconvulsive status epilepticus. A new epileptic syndrome. *Brain.* 1997;120(6):939–53.
45. Myers KA, Bennett MF, Hildebrand MS, Coleman MJ, Zhou G, Hollingsworth G, et al. Transcriptome analysis of a ring chromosome 20 patient cohort. *Epilepsia.* 2021;62(1):e22–e28.
46. Elens I, Vanrykel K, De Waele L, Jansen K, Segeren M, Van Paesschen W, et al. Ring chromosome 20 syndrome: electro-clinical description of six patients and review of the literature. *Epilepsy Behav.* 2012;23(4):409–14.
47. Schiller K, Dassi C, Berrahmoune S, Frauscher B, Myers KA. Sociocultural factors influence on burden and stress of caregivers of children with epilepsy. *Can J Neurol Sci.* 2025;52(2):322–6.
48. Zulfiqar Ali Q, Marques P, Patel P, Carrizosa J, Nabbout R, Andrade DM. Transition in epilepsy—a pilot study with patients in and outside of academic centers. *Epilepsy Behav.* 2024;151:109624.

SUPPORTING INFORMATION

Additional supporting information can be found online in the Supporting Information section at the end of this article.

How to cite this article: Khamis A, Ricci E, Canevini MP, Lagae L, Tokumoto K, Inoue Y, et al. Management of ring chromosome 20 syndrome: Narrative review and consensus recommendations. *Epilepsia.* 2026;00:1–11. <https://doi.org/10.1002/ept.70266>